

ATYPICAL PRESENTATION OF TAKAYASU'S ARTERITIS – TAKAYASU'S ARTERITIS WITH DILATED CARDIOMYOPATHY

R. K Vidyabati Devi

Asst. Professor, Dept. of Biochemistry, JNIMS
E-mail: vidyarakumari@gmail.com

ABSTRACT

A young female was diagnosed with Takayasu's arteritis based on clinical features, investigations and resolution of symptoms with steroids. This case illustrated that Takayasu's arteritis can have varied presentation and early diagnosis along with treatment has improved the symptoms and prevented the classical manifestation of Takayasu's arteritis.

Key words: Takayasu's arteritis, CRP, ESR, DOPPLER.

INTRODUCTION

Takayasu's arteritis is a nonspecific inflammation of the aorta often affecting the ascending aorta causing obstruction of the aorta and its major arteries. It is also called pulseless disease. The disease is most prevalent in young female of Asian origin. Pathology is panarteritis, characterized by inflammatory mononuclear cell infiltrates and occasionally giant cells with marked intimal hyperplasia, medial and adventitial thickening leading to fibrotic occlusion.

CASE

A young female of 20 years admitted with dyspnoea on exertion, fever, malaise and cough for 1 month duration. On clinical examination, mild pallor +ve, febrile. BP 160/70 mm Hg. SPO₂ 99%, HR 158/min on right upper arm and BP cannot be recorded and pulse cannot be felt on the left upper limb. Carotid bruit heard. CVS - systolic murmur +ve, S3 +ve. Respiratory system was normal.

INVESTIGATION

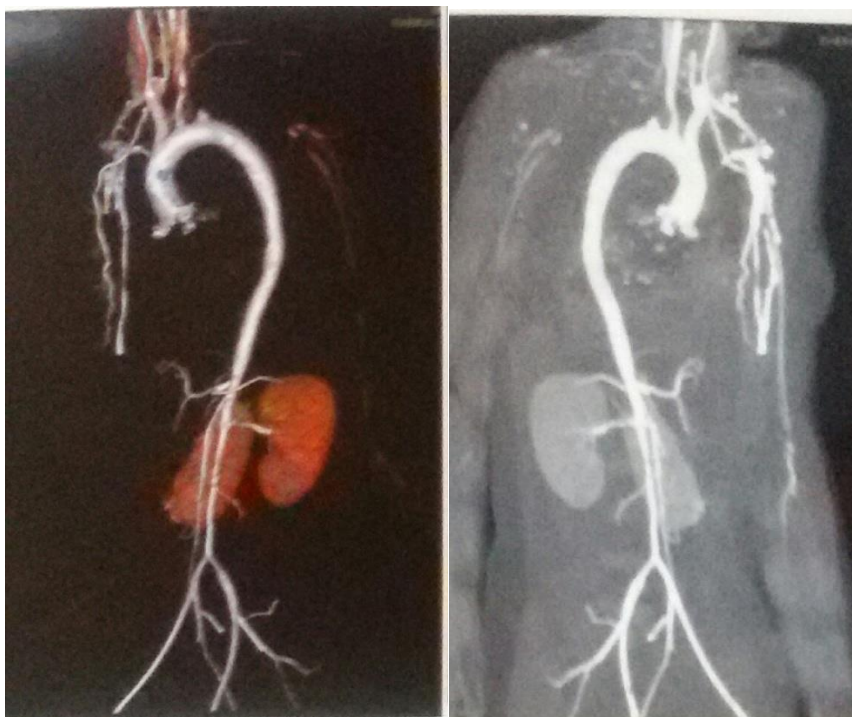
Raised ESR 155mm at 1st hr, Hb. 9.7 g %, Prothrombin time - 15 sec, INR- 1.28 C Reactive protein and S. ferritin were raised markedly >11mg/l Anti ds DNA and ANA were normal. Liver function- enzymes SGOT, SGPT slightly raised, S. lipid profile was normal, Kidney functions were normal, Urine examination showed traces of protein and sugar, ECG indicated sinus tachycardia, X ray chest suggestive of cardiomegally.

ECHOCARDIOGRAPHY

LVEF 27 %, all chambers dilated, global hypokinesia with severe LV systolic dysfunction. Doppler study of bilateral lower limb shows arteritis involving bilateral limbs with pulsatile venous flow.

CT Abdomino Aortography

Shows features suggestive of aortic arteritis involving lower thoracic and abdominal aorta, bilateral common carotid and left subclavian arteries. With the confirmed diagnosis, she was treated with steroids, beta blockers and ACE inhibitors. Symptoms improved.



Fig; CT Aortography showing bilateral narrowing of lower thoracic and abdominal aorta, bilateral common carotid and left subclavian arteries

DISCUSSION

The diagnosis of Takayasu's arteritis is strongly supported by investigation findings and improvement of symptoms by steroids. This illustrated that Takayasu's arteritis may present with atypical

presentation before the classical manifestation sets in.

ECHOCARDIOGRAPHY

Should be done in all patient of TAKAYASU'S ARTERITIS as it can be the only manifestation sub clinically.

REFERENCE:

1. Creager et al: Disease of Aorta. 17 edition Harrisons II.
2. Creager et al: Vasular Medicine;A companion to Braunwald :s Heart Disease, 1st Philadelphia, Saunders, 2006.
3. GOLOMB BA et al; Peripheral Arterial disease; Morbidity and mortaliy implacations. Circulations 114:688, 2006
4. HANKEY GJ et al:Medical treatment of peripheral arterial disease. JAMA 295:547. 2006
5. White C; Clinical practice. Intermittent claudication. N Engl J Med 356:1241, 2007.